

Pancreaticoduodenectomy for periampullary adenocarcinoma

SECI experience

Gamal Amira MD, Doaa Wadie MD

Introduction

Periampullary carcinoma is a major public concern throughout the world. The periampullary malignancy is the ninth most common cancer and is the fourth and fifth leading causes of cancer deaths in men and women, respectively.

Pathological examination of resected specimens showed that adenocarcinoma of the head of the pancreas (40 % to 60%), account for the vast majority of periampullary neoplasm. followed by adenocarcinoma of the ampulla of Vater (20% to 40%), distal bile duct (10%), and duodenum (10%).

Pancreaticoduodenectomy is the only potentially curative treatment for pancreatic periampullary tumors. However, postoperative morbidity and mortality are high, and different approaches have been tried to improve the results. Despite a decrease in recent years, the postoperative mortality after PD remains as high as 8%. The median period of survival is 1.5 year, the 5-year survival rate is 15%.

Aim of the work

to analyze the surgical procedures, mortality and morbidity after pancreaticoduodenectomy for periampullary carcinoma.

Patients and Methods

From November 2004 to November 2006, 15 patients with periampullary carcinoma in South Egypt Cancer Institute, Assiut University were operated upon.

(A) Patients selection:-

All patients fulfilled the Following: -

*Age less than 70 years.

*Clinically suspected periampullary carcinoma which include;-

1-carcinoma of the distal common bile duct.

2- carcinoma of the pancreatic head.

3- Carcinoma of periampullary duodenum.

4-Ampullary carcinoma (any tumor arising within 1 cm of the ampulla of Vater).

* Adequate hepatic and renal function guided by liver function, serum creatinine and CBC.

* No previous history chemotherapy or radiotherapy treatment .

* No history of cardiac disease.

(B)Methods

A-Pre-operative staging:-

1-Trans-abdominal ultrasonography was the initial imaging modality to exclude cholelithiasis and confirm obstruction to the

extra-hepatic biliary tree. In addition, the presence of a large pancreatic mass lesion, portal vein thrombosis, extra-pancreatic lymphadenopathy and hepatic metastases are usually indicative of incurable disease.

2- Computed tomography; -contrast enhanced triple phase helical CT scan was carried out with thin cuts to provide arterial (3mm) and venous phase (3 or 5mm) cross sectional imaging. This modality is most useful when US is equivocal or when visualization is obscured by gas or ascites. (Fig 1).

- It is better in evaluating operability and preoperative staging; it gives better assessment of invasion or compression of vessels and adjacent organs.

-Resectability of the tumor by CT was established by absence of liver metastases, suspected distant malignant adenopathy, encasement of the celiac or superior mesenteric arteries, or encasement-thrombosis of the superior mesenteric or portal vein.

SOUTH EGYPT CANCER INST.
2000S 3804

ANT

7-D #20

Loc: 1279 mm

Active

X : 0.0 mm

Y : 0.0 mm

Z : 1229.1 mm

Zoom 1.0/ X

MOHAMMED A. ELNAEIM 4

ID: 641

CONT: +

1110/2K Avail : 21040K Req

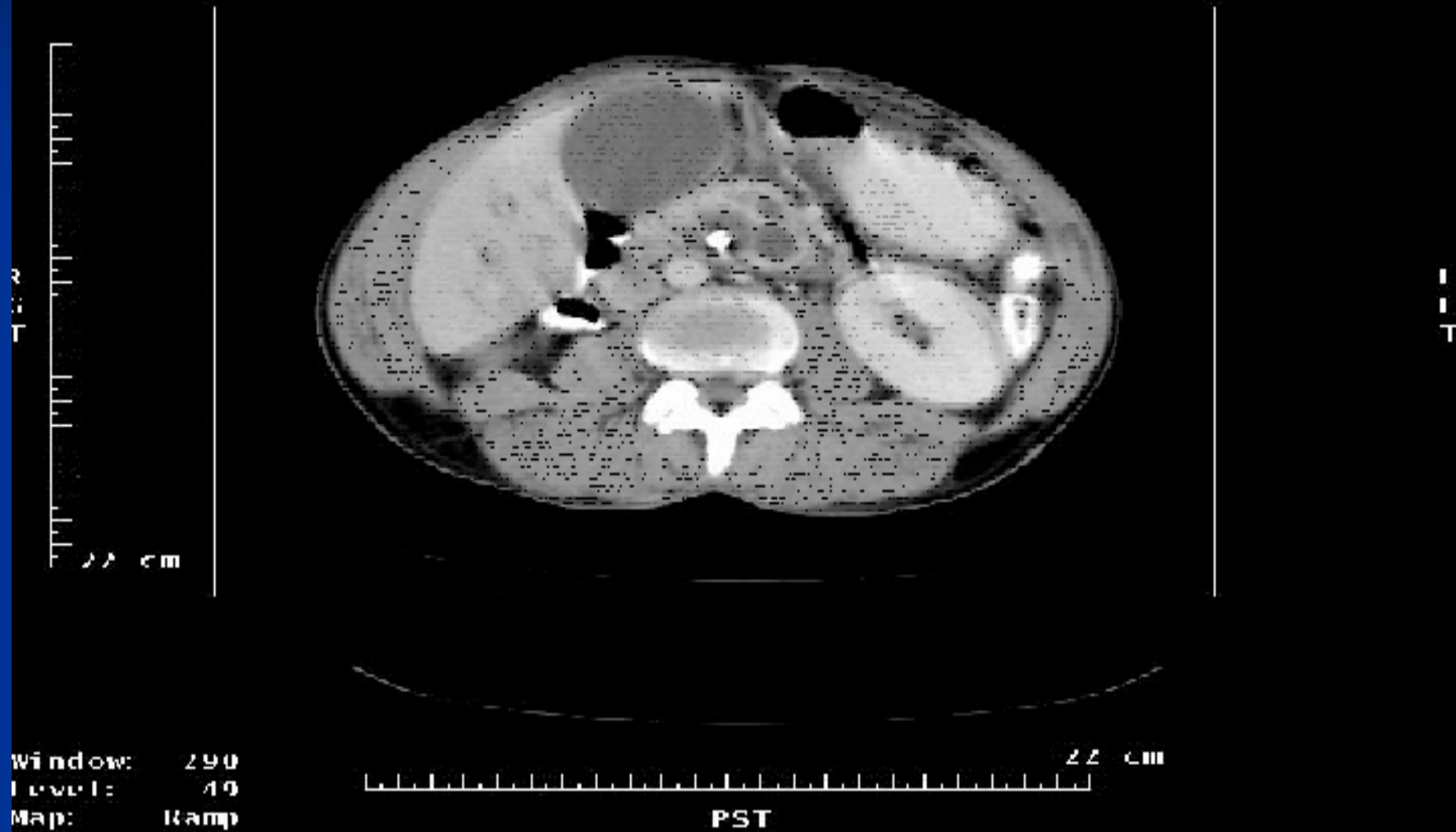

Figure (1) preoperative CT with pancreatic head mass and visible stent

B-Surgery:-

Skin incision:

Bilateral sub-costal incision was made in all cases and this provides adequate access and exposure (fig 2).

At the time of surgery, patients were explored with intent for curative resection.

. Patients were initially explored to examine:-

1-The presence of previously undetected metastases in the liver, mesentery, or peritoneum.

2-The involvement of major vessels; portal vein, superior mesenteric vein (SMV), superior mesenteric artery, hepatic artery, and celiac axis.



Figure (2) show bilateral subcostal skin incision

Preliminary duodenal and pancreatic exposure

The key of this resection is the exposure of the superior mesenteric vein (SMV) and the anterior surface of the head and neck of the pancreas. This was achieved by mobilization of the hepatic flexure and right half of the transverse colon, which was reflected downwards towards to the midline (Fig 3)

Kocherisation of the duodenum and pancreatic head .

The duodenum was kocherised from the patient right side using diathermy or scissor dissection to widely expose the infra-hepatic IVC, left renal vein and infra-renal aorta. (Fig 4)

Resectability relative to the SMA was confirmed by lifting the head of the pancreas in the left hand between the fingers posteriorly and thumb anteriorly, to ensure the tumor is clear of the SMA.

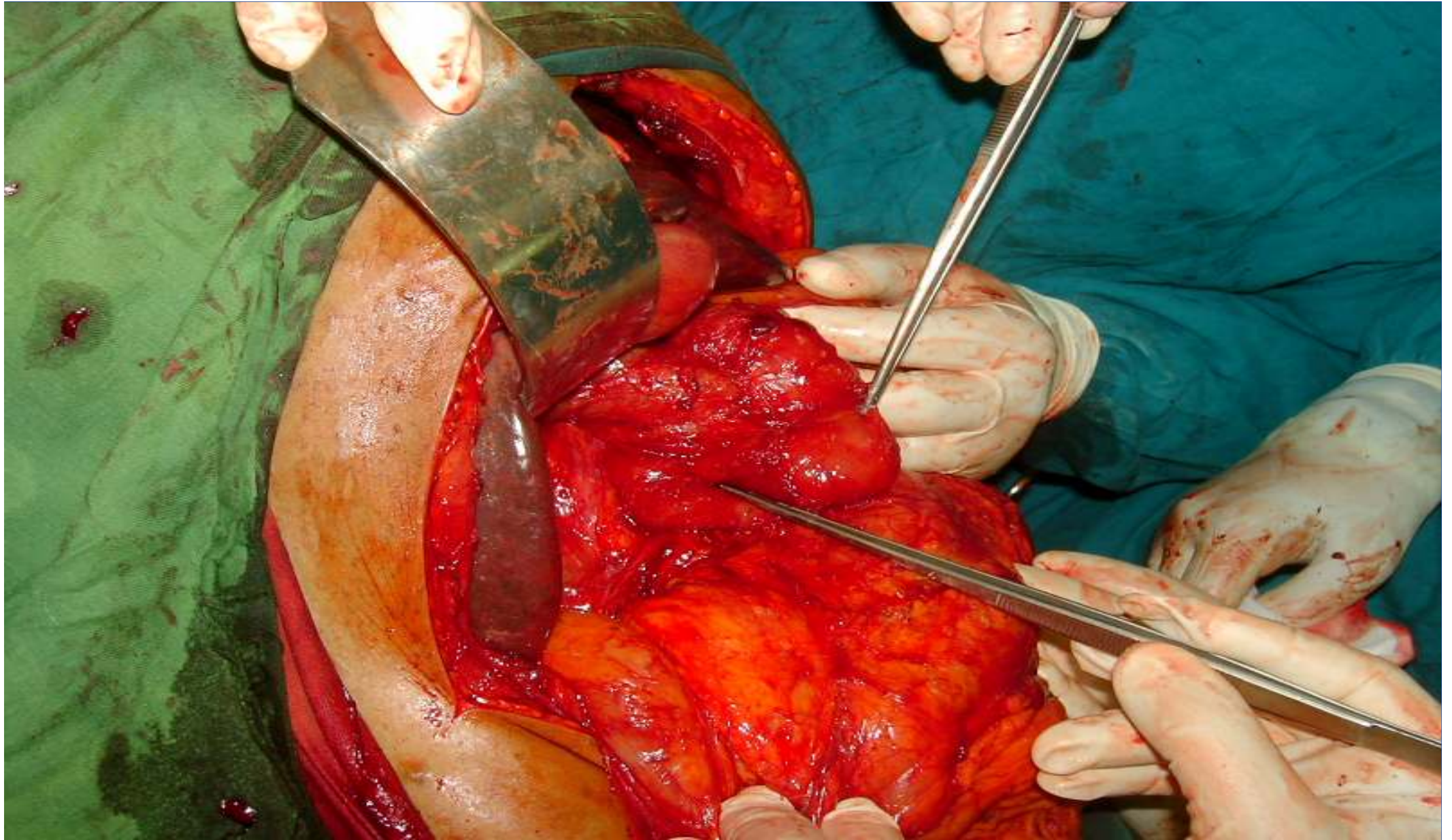


Figure (3) shows mobilization of the hepatic flexure and right half of the transverse colon.

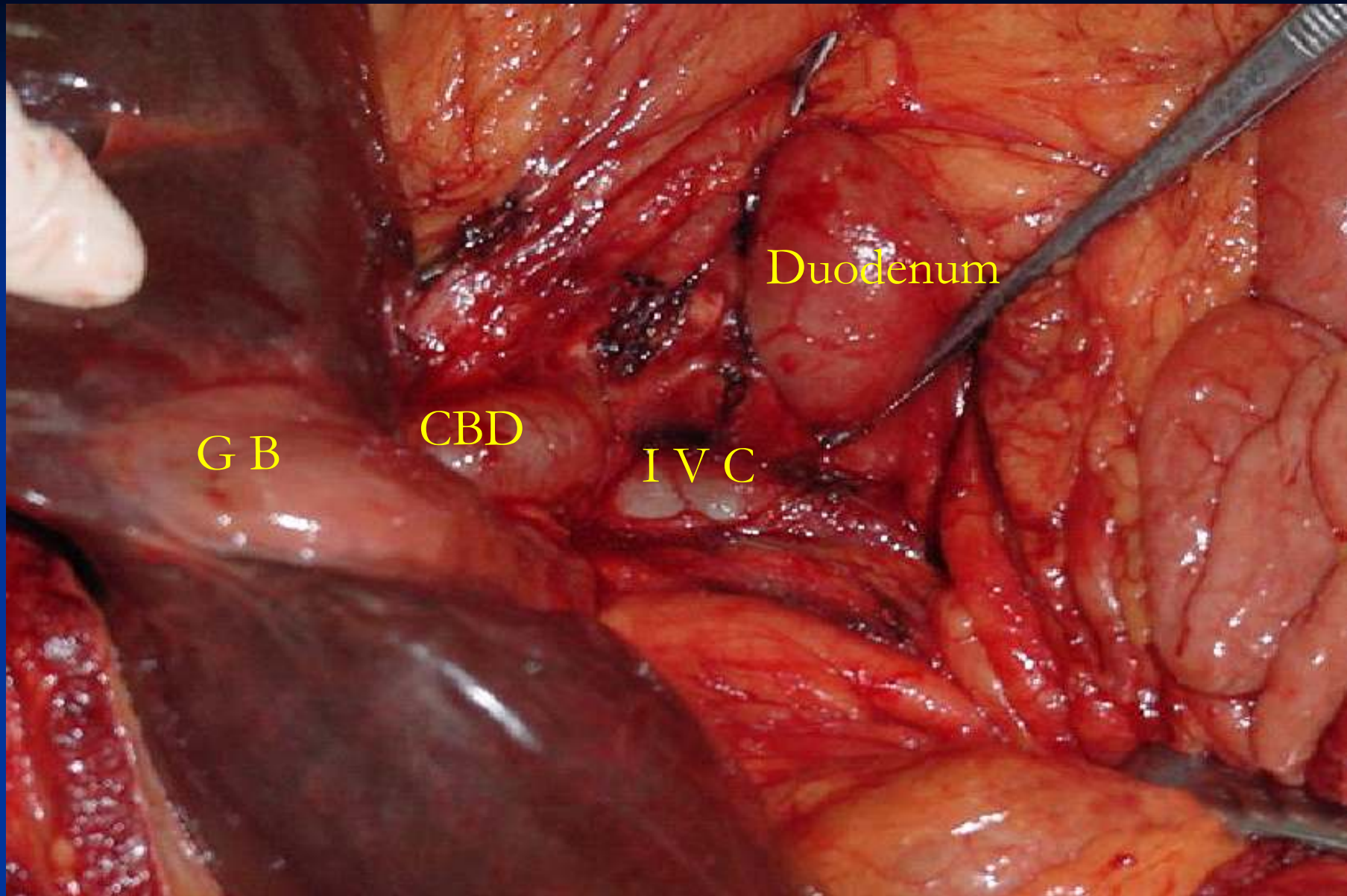
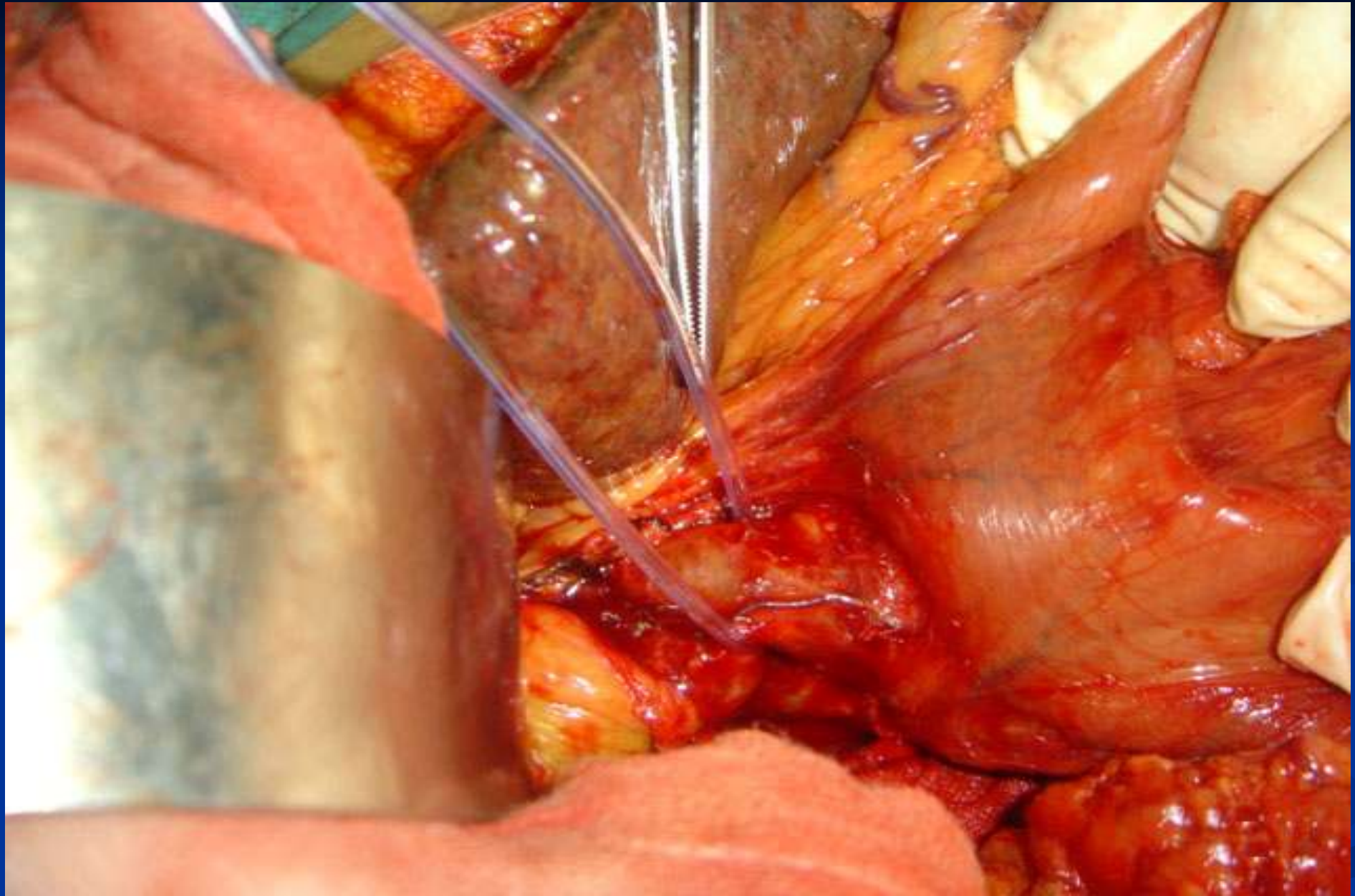


Figure (4) shows Kocherization of the duodenum and exposure of IVC



Kocherization of the duodenum

Hepatoduodenal dissection / exposure of portal vein.

The gastrohepatic ligament was divided close to its insertion into the liver, with care being taken to preserve an aberrant left hepatic artery if present. This dissection was continued to expose the main portal inflow structures.

The gall bladder was mobilized first from the hepatic fossa using diathermy dissection.

The cystic artery was ligated and divided, leaving the gall bladder in continuity with the main bile duct to provide traction during mobilization of the bile duct and lymphatics off the portal vein. The main bile duct was divided above the insertion of the cystic duct.

The distal duct was ligated and the proximal common hepatic was left unclamped to drain into small swab (fig.5,6).

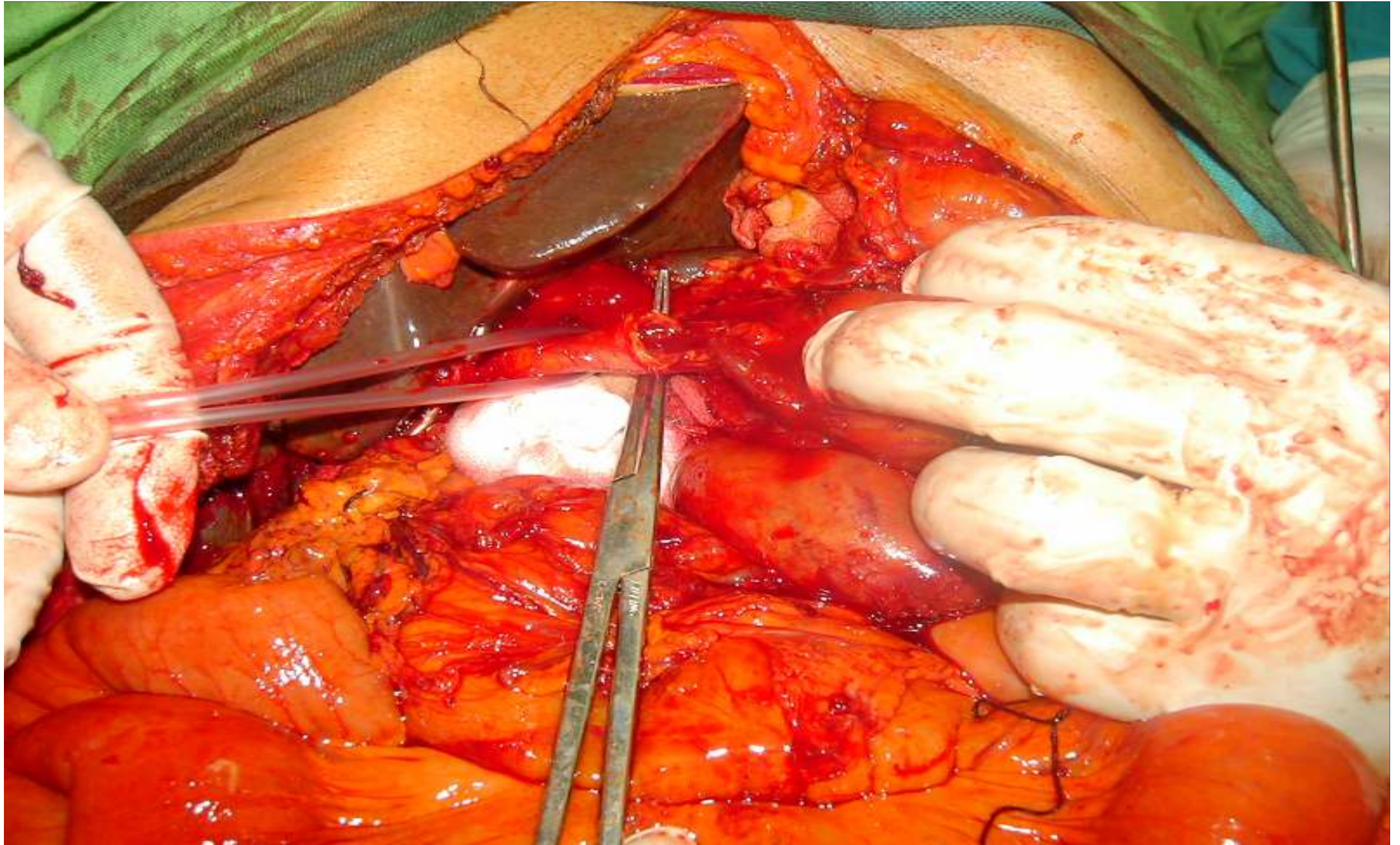


Figure (5) The CBD was cut to drain into a swab

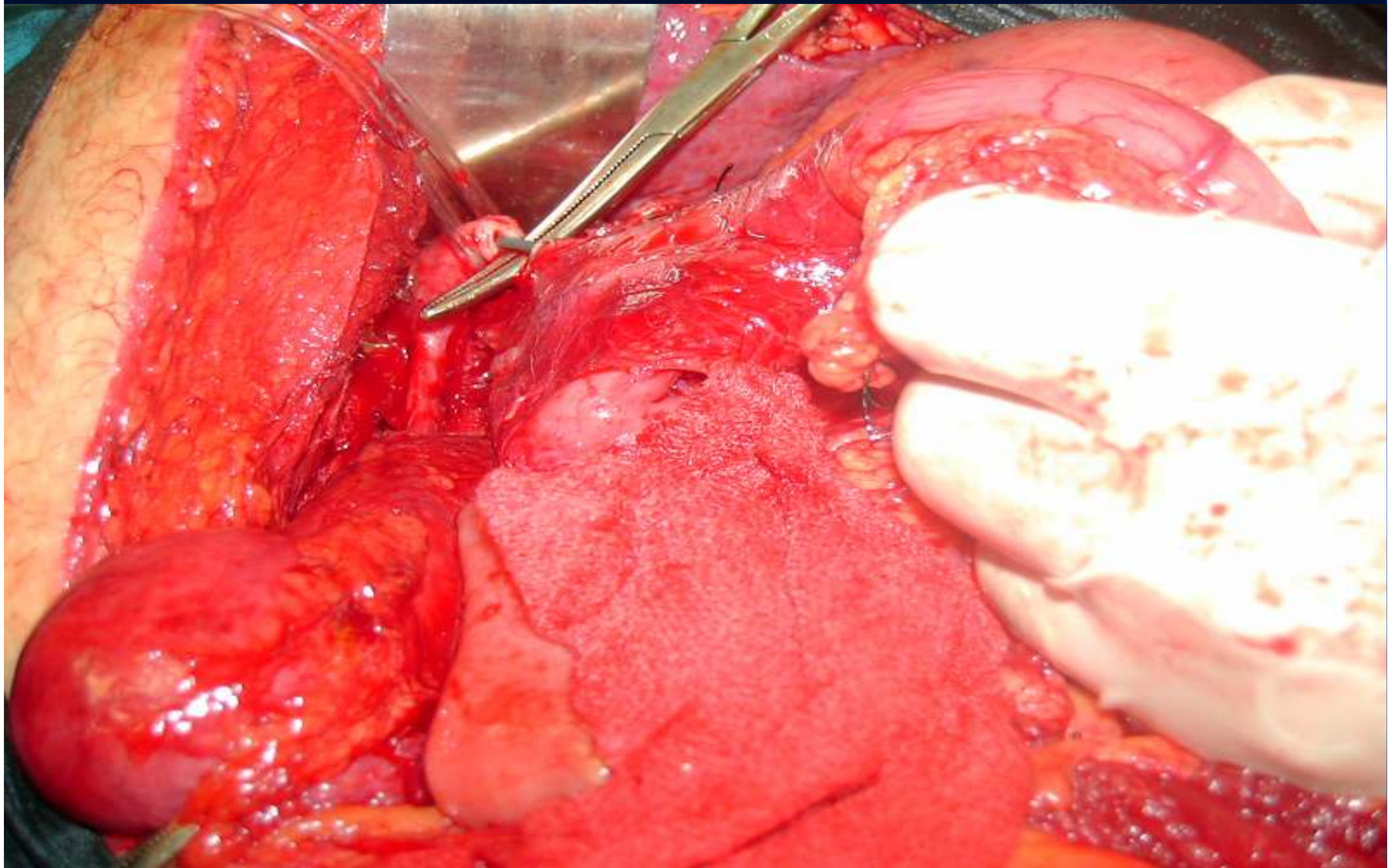


Figure (6) shows stent inside CBD

Gastric transection

The stomach was divided and the antrum was rotated to the right to expose the head and the neck of the pancreas (Fig.7) .the proximal stomach was packed away into the left upper quadrant. In three cases pylorus preservation were done. (Fig.8)

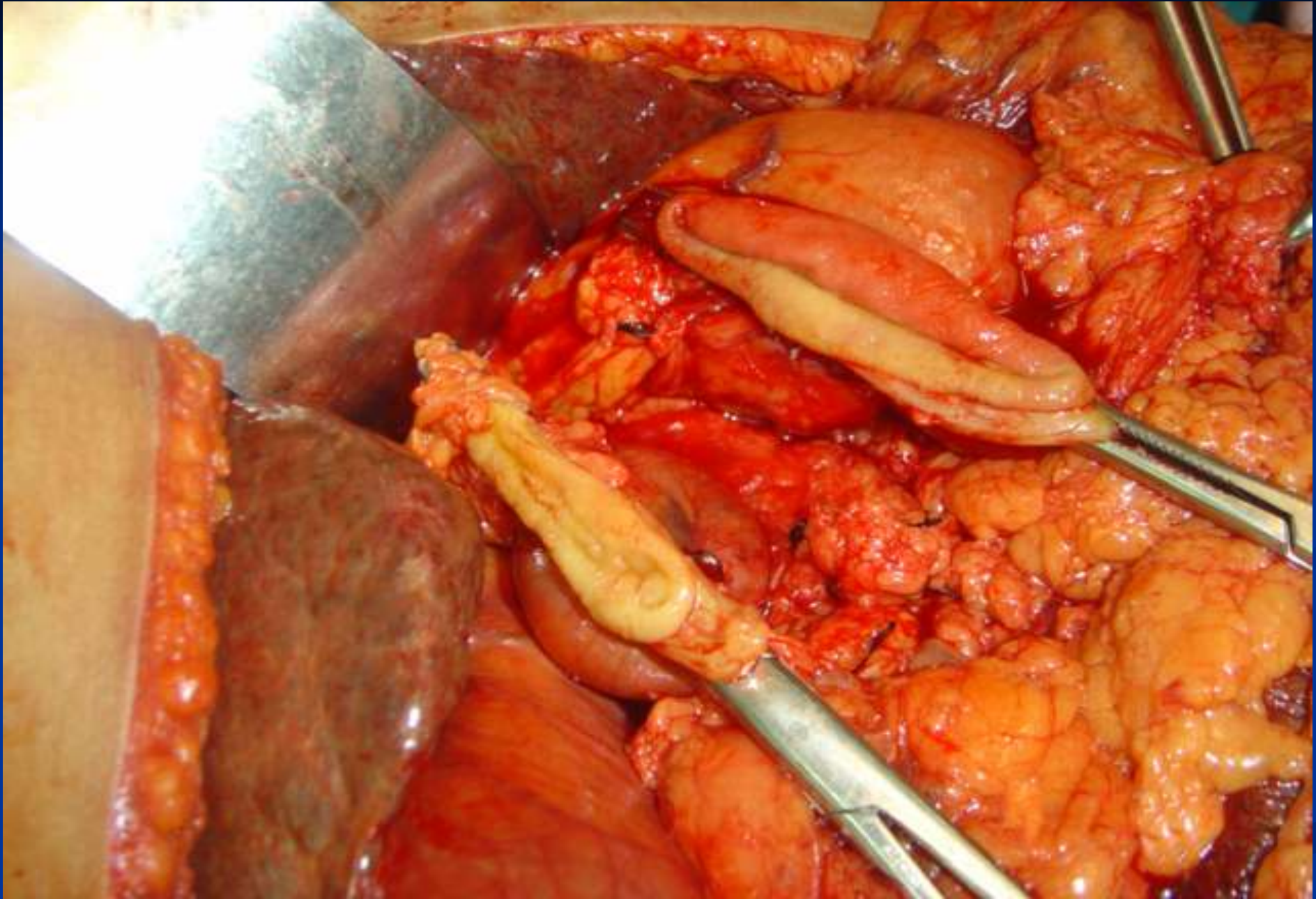

Figure (7) gastric resection

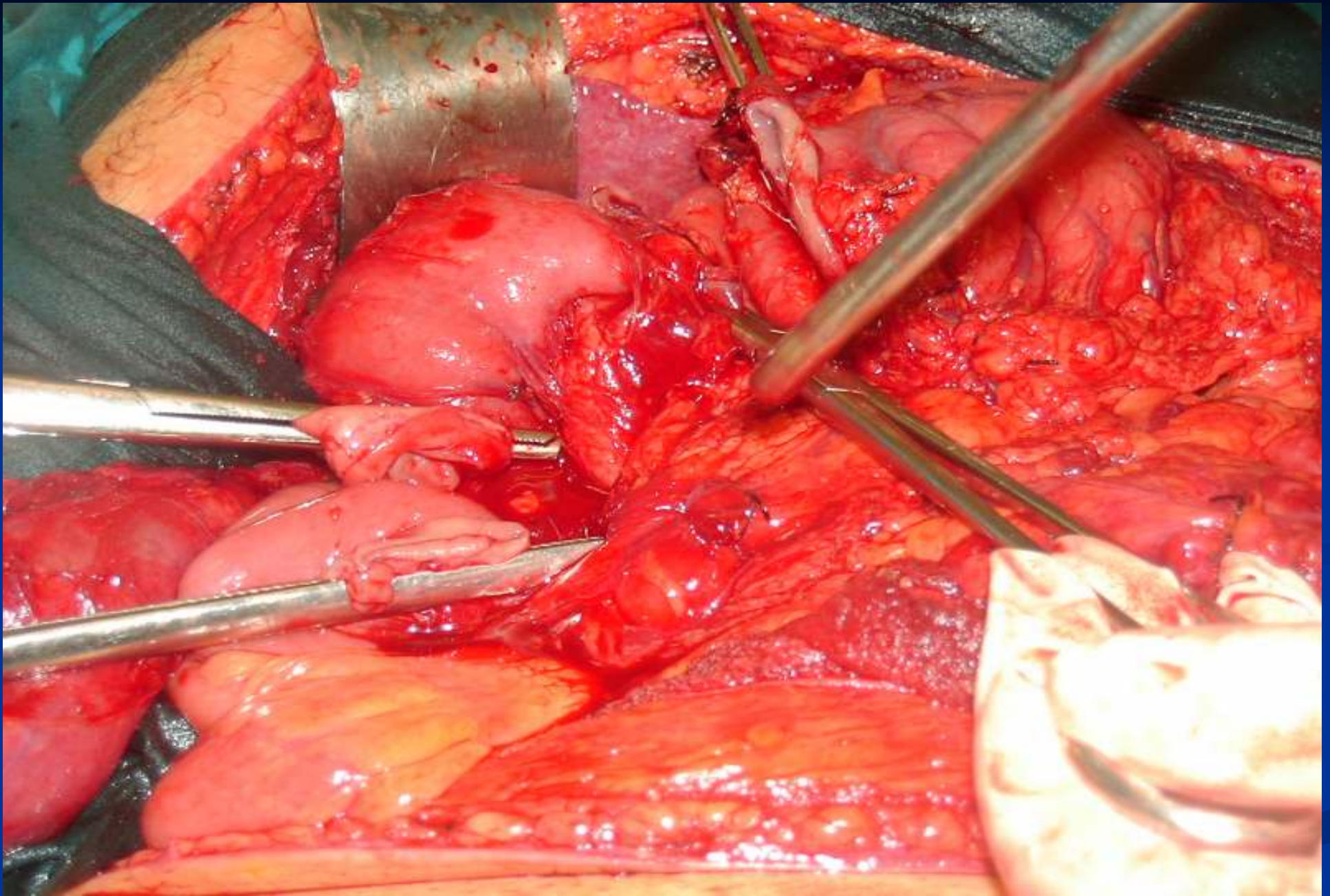


Figure (8) pylorus preservation

Pancreatic resection

The sling elevates the pancreatic neck and 4 stay sutures were inserted into the superior and inferior borders of the pancreas fig(9).

The pancreas was transected to include the head,neck,and part of the body with 2.5 cm safety margin

DJ flexure mobilization

The proximal jejunum and ligament of Treitz were mobilized by division of the lateral peritoneal attachments. The jejunum was divided 15 cm beyond the ligament of Treitz. (Fig. 10).

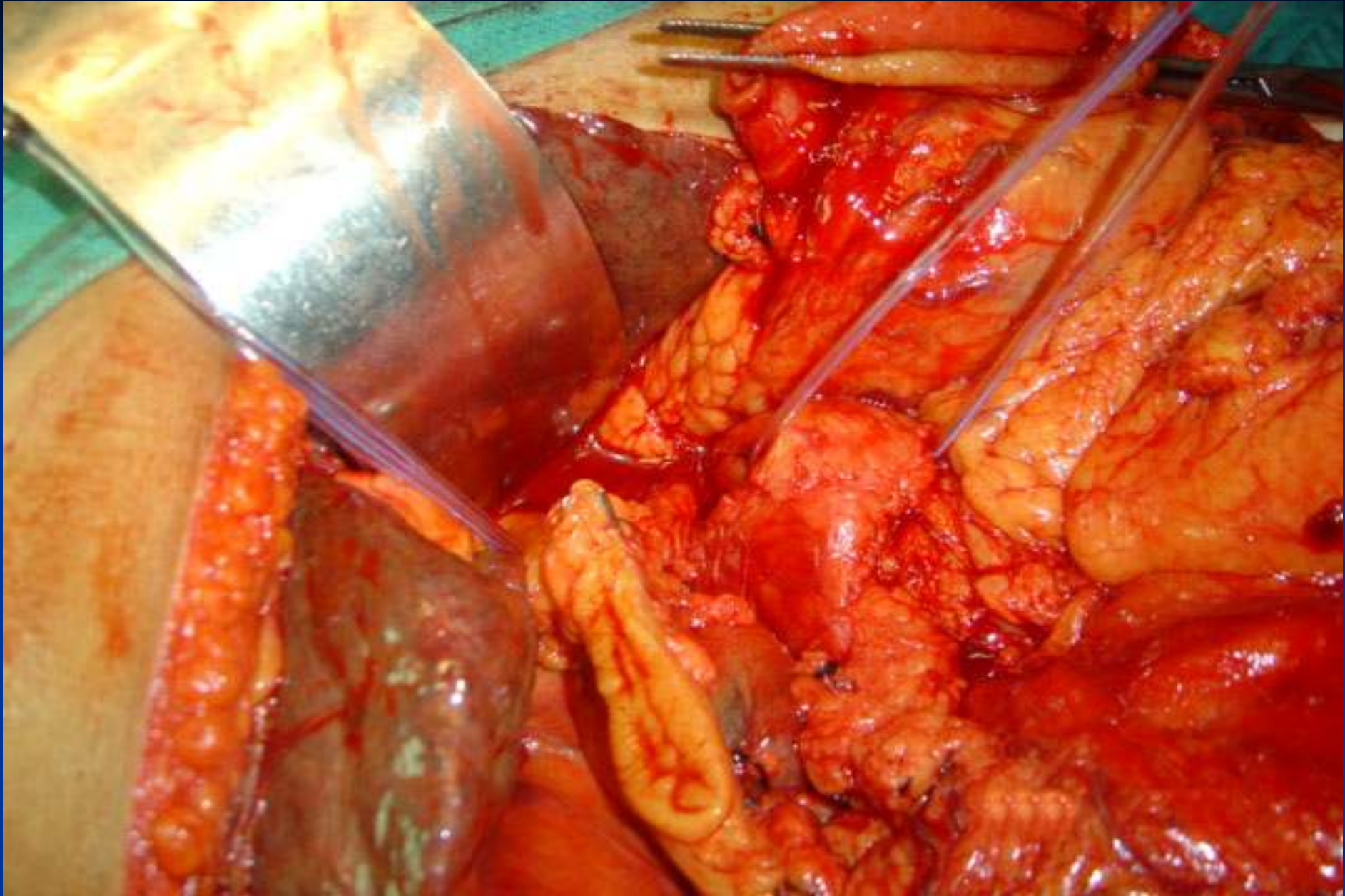
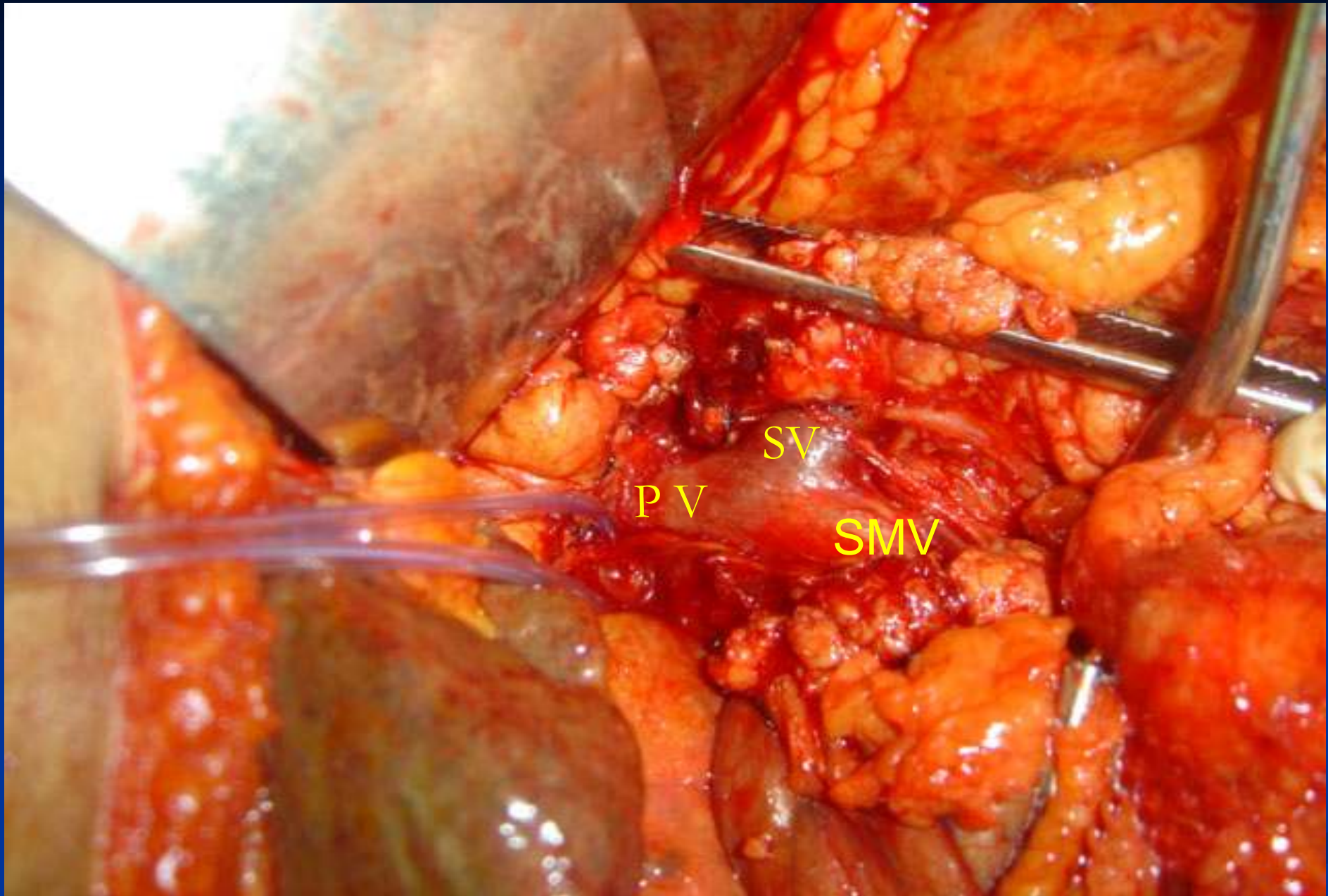
Figure (9) The sling elevates the pancreatic neck



Exposure of the portal vein with the confluence of the SMV and SV.

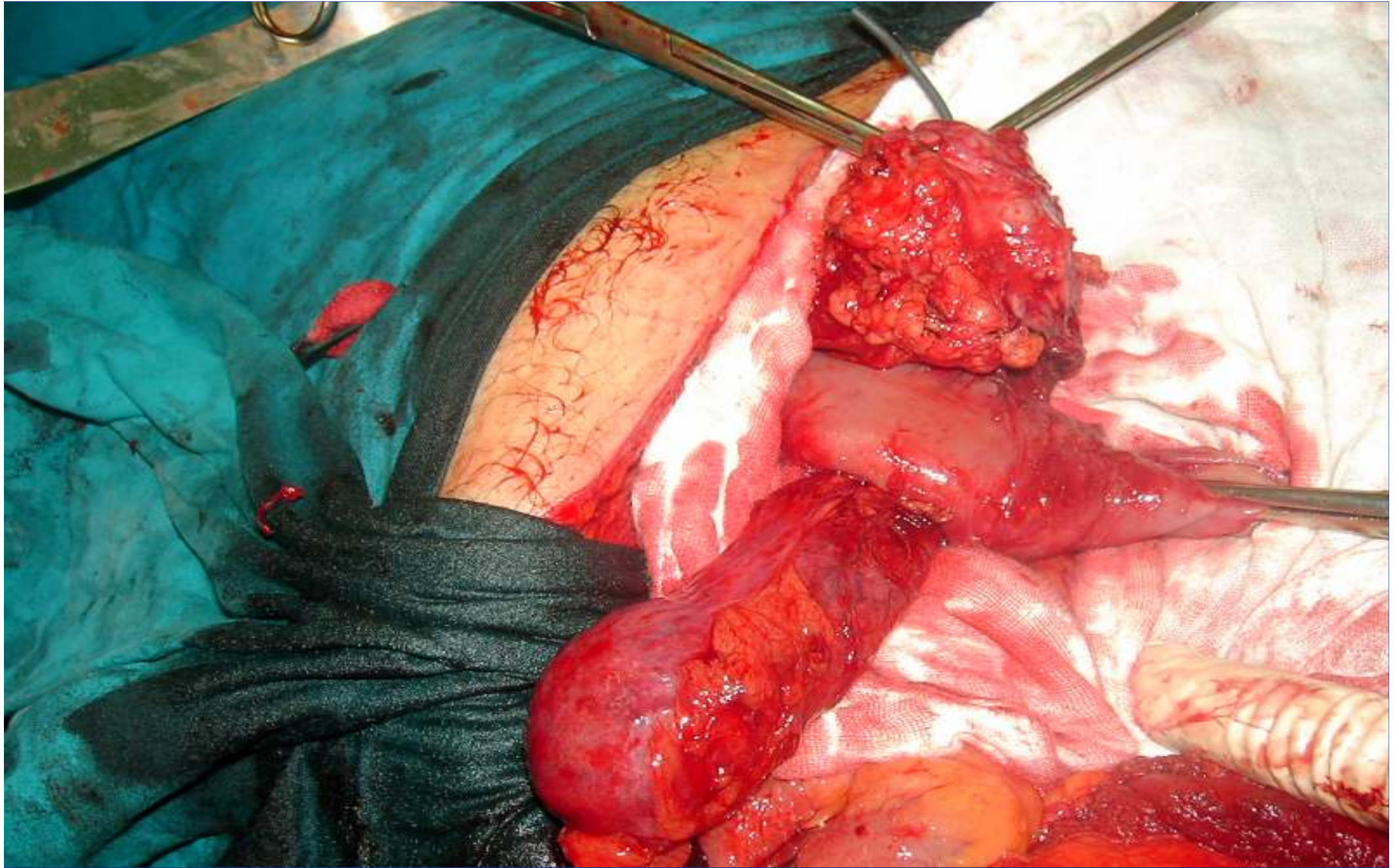


Figure (10) transection of the jejunum

Surgical Reconstruction

Pancreatic anastomosis

Pancreatic anastomosis was done end to side pancreaticogastrostomy. The pancreatic remnant was freed from the retroperitoneal space for about 3 cm. A corresponding transverse opening was made on the posterior gastric wall (fig.12)

The anastomosis was performed with an interrupted row 3/0 silk suture. A stent tube was inserted and fixed to the pancreatic duct. (Fig.13).

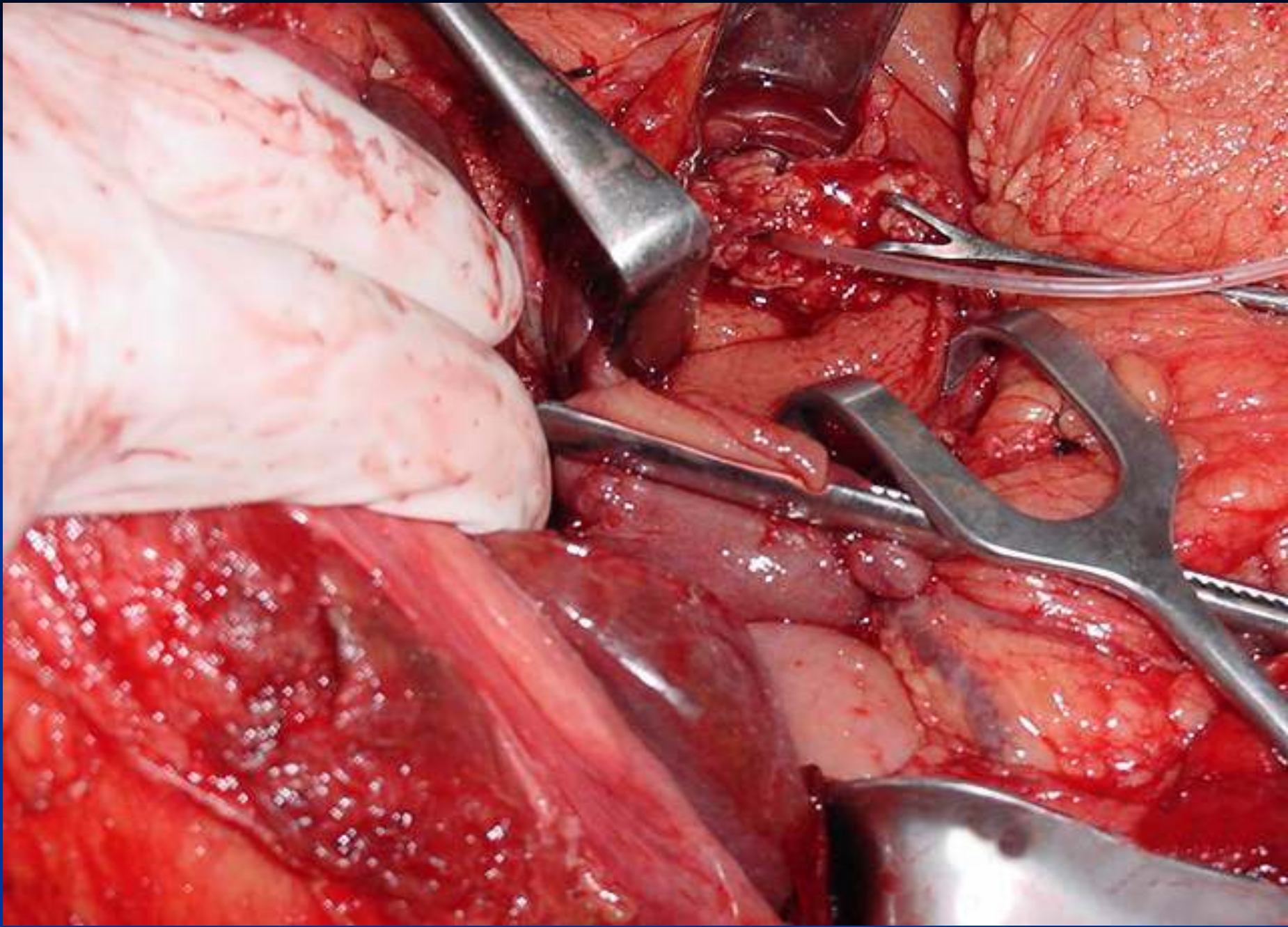

Figure (12) shows method of pancreaticogastrostomy

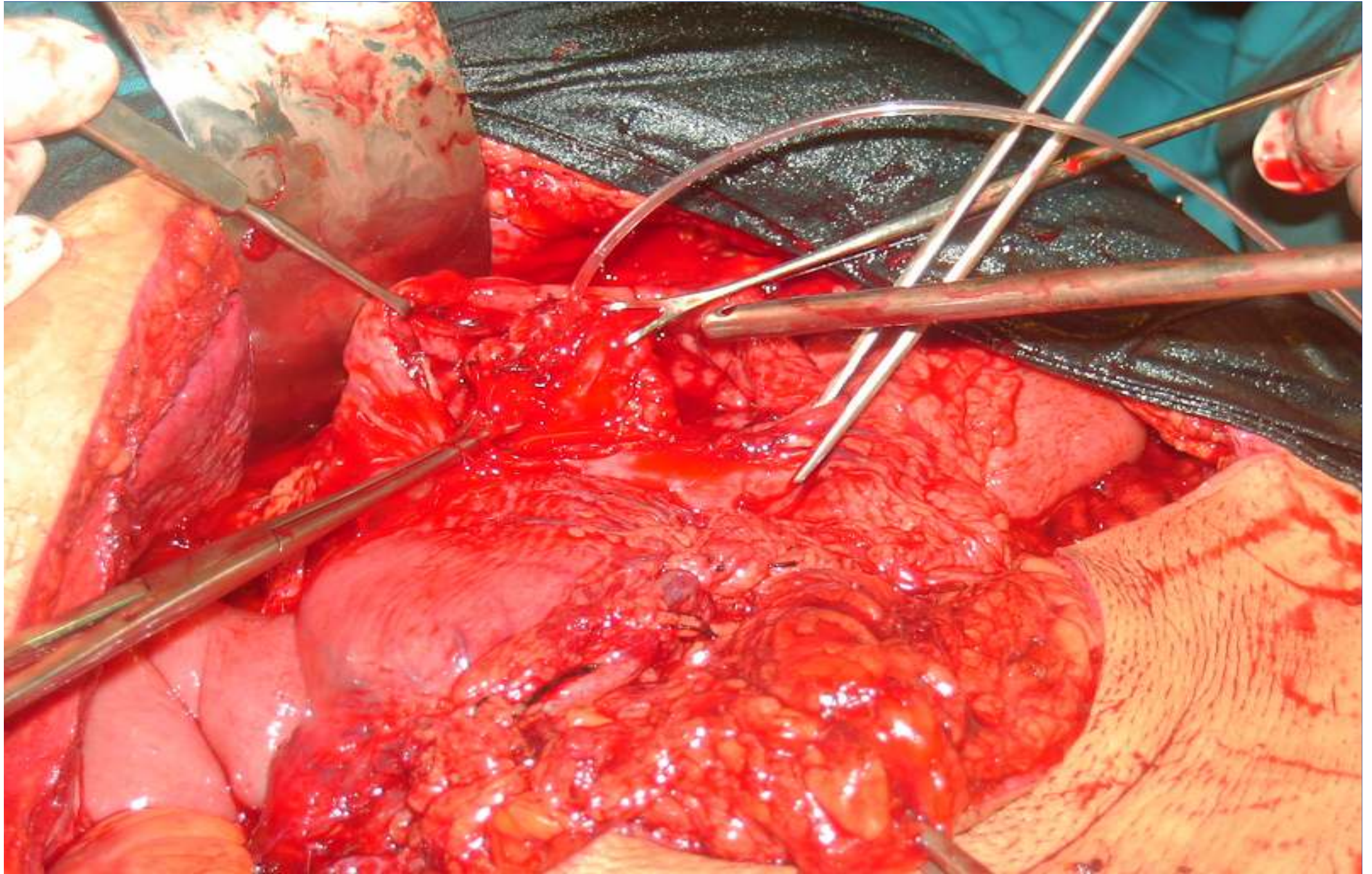


Figure (13) shows stent inside the pancreatic duct

Biliary anastmosis

An end-to-side hepaticojejunostomy was fashioned in 12 patients using single layer of interrupted 4/0 absorbable sutures. Sometimes the CHD was so dilated that, end –to –end hepaticojejunostomy was done in 3 patients (Fig.14).

Gastric anastmosis

An end-to-side gastroentrostomy was fashioned 50 cm downstream from the biliary anastmosis in 2 layers using 3/0 absorbable sutures in 10 patients and end to end gastrojejunostomy in 5 patients (including the 3 patients with pylorus preservation).

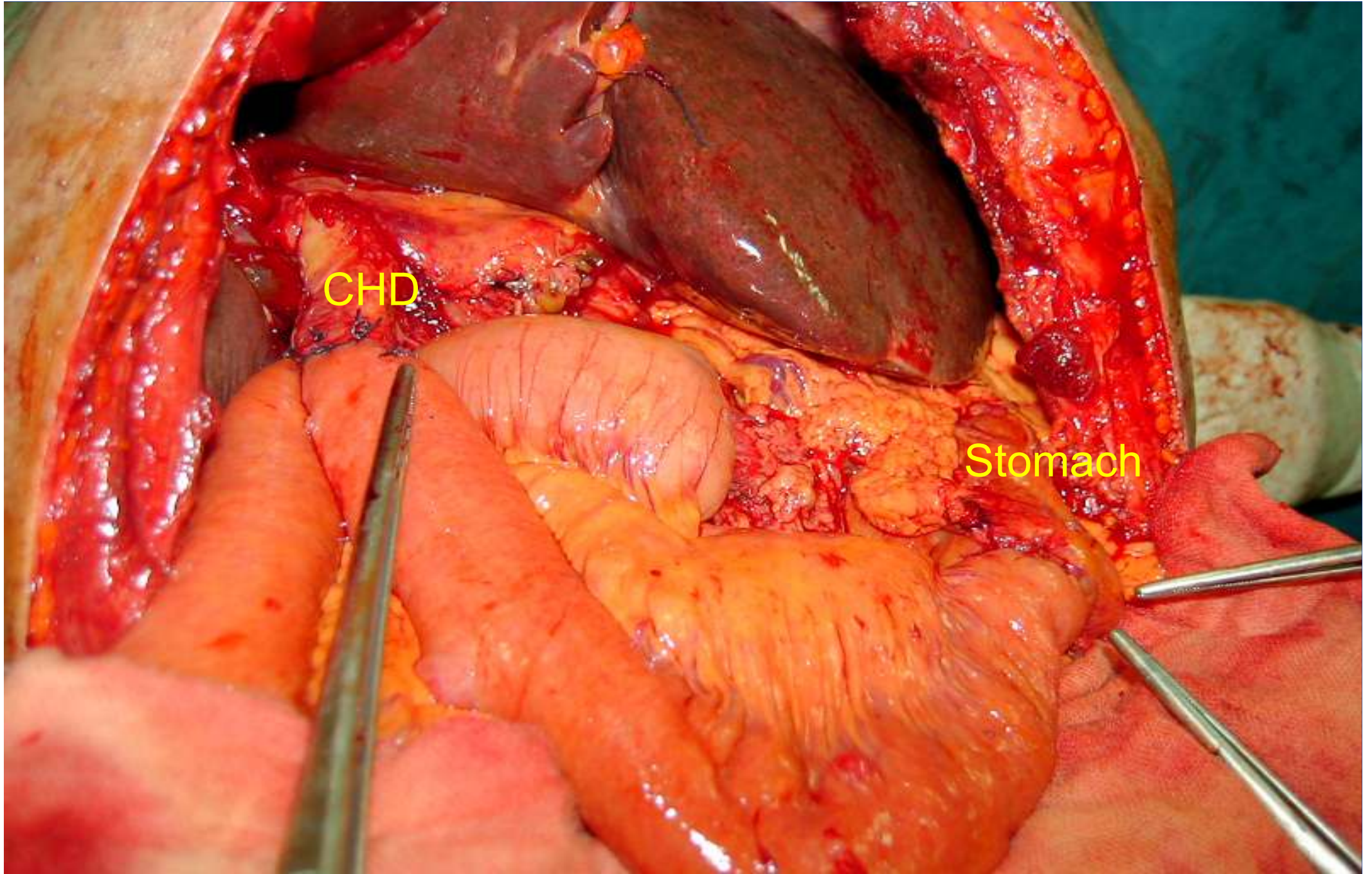


Figure (14) shows hepatico-jejunostomy and gastroenterostomy.

Drainage and closure

The abdominal cavity and operative site was irrigated with warm saline and aspirated dry. Two size 5mm closed silicon drains were placed into the abdomen via separate stab incisions .One from the left was placed below the left lobe of the liver anterior to the pancreatic anastmosis, and the second was placed from the right side to the hepatorenal space. The incision was closed en-mass using looped absorbable sutures.

Post operative morbidity and mortality:

2 patients (13.3%) died postoperatively:

one due to reactionary hemorrhage from the portal vein.

one due to respiratory failure on the 6th postoperative day.

morbidity includes:-

Minor biliary leakage that healed conservatively in one patient (6.6%); leakage from gastrointestinal anastomosis that healed conservatively in one patient (6.6%). No complications were found in the pancreaticogastrostomy anastomosis.

Delayed gastric emptying occurred in 4 patients (26.6%) (in 2 of the patients with pylorus preservation and in 2 patients without pylorus preservation)

The mean hospital stay was 19 days . During follow-up two patients developed local recurrence and one patient had liver metastasis, (fig15).

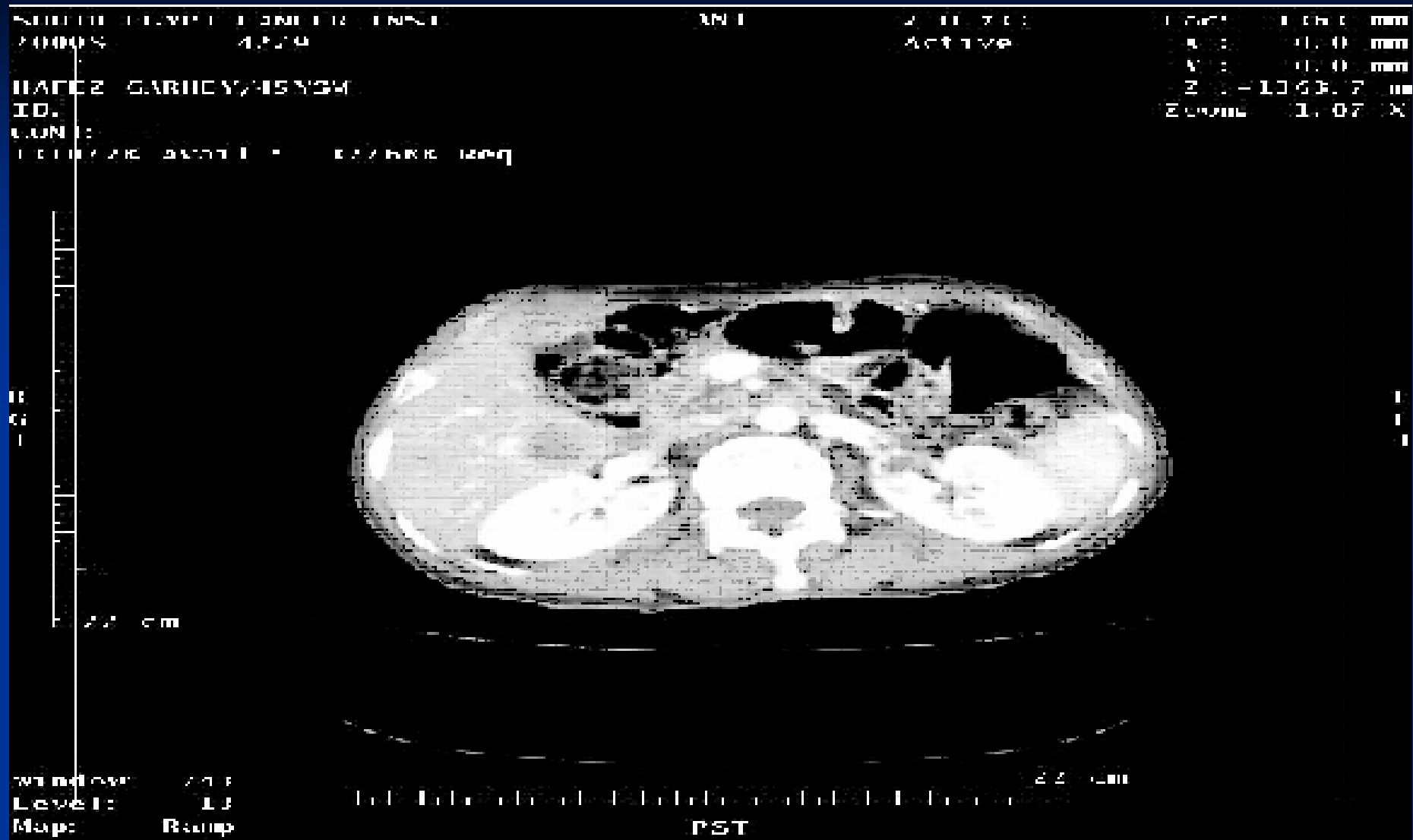


Figure (15) Postoperative CT showing liver metastasis after PD.

Conclusions

Surgery remains the main stay of periampullary carcinoma and surgical resection of the tumor provides the only chance of cure. Improvements of surgical techniques, increased surgical experience and advances in postoperative intensive care and parenteral nutrition have substantially decreased the risk of pancreaticoduodenectomy in recent years. This is reflected in a decrease in the operative mortality rate from over 20% to below 5% in several large centers throughout the world.

As regard the method of reconstruction after pancreaticoduodenectomy, pancreaticogastrostomy was done in all the cases, and there was no leakage from the pancreatic anastmosis, so we conclude that pancreaticogastrostomy is a good reconstructive method and associated with low morbidity and mortality and that it contributes to the re-establishment of a physiologic way of digestion and absorption.

Thank you